

FACIAL NERVE AND ACOUSTIC NEUROMA

POSSIBLE DAMAGE AND REHABILITATION

INTRODUCTION

At the time most people learn they have an acoustic neuroma, they are also told that this tumor may involve the facial nerve that controls facial movement. The patient may find it difficult to grasp the connection between a benign growth on the nerve of hearing (the eighth, or acoustic nerve) and any compromise of the facial nerve (the seventh). In the 2007-2008 AN patient survey, 28% of the respondents reported facial weakness or paralysis, some of which were before and some were after treatment. This represented a significant improvement from the 1998 patient survey of post-treatment acoustic neuroma patients which revealed that at the time they completed the survey, only 59% were satisfied with the appearance of their face.

People scarcely appreciate the exquisite musculature of the face that allows them to express themselves through speech and emotional expression—from wide-mouthed laughter to scowling disapproval. The eyes blink and are precisely moistened. Taste, a sensation that reflects accurately sweet, sour, bitter and bland, is also a function of the facial nerve.

Treatment for an acoustic neuroma may damage the facial nerve – either with surgery or radiation. It is usually possible, however, to preserve some degree of facial nerve function even in cases where the nerve is extensively involved. For those with partial nerve regeneration, in whom some facial weakness remains, non-surgical facial rehabilitation therapies, Botox treatment, and reconstructive surgery may be available.

LOCATION AND UNIQUE QUALITIES OF THE FACIAL NERVE

The facial nerve is one of a set of twelve cranial nerves originating from each side of the brainstem. (Other nerves control hearing, balance, transmission of vision images to the brain, smell, eye movement and other functions.)

The facial nerve originates from the medulla portion of the brain, emerges from the pons, courses through a small area in the lower back section of the brain where several soft tissue structures meet (the cerebellopontine angle), then runs through a small bony canal (the internal auditory canal) where it closely approximates the eighth cranial nerve (Figure 1).

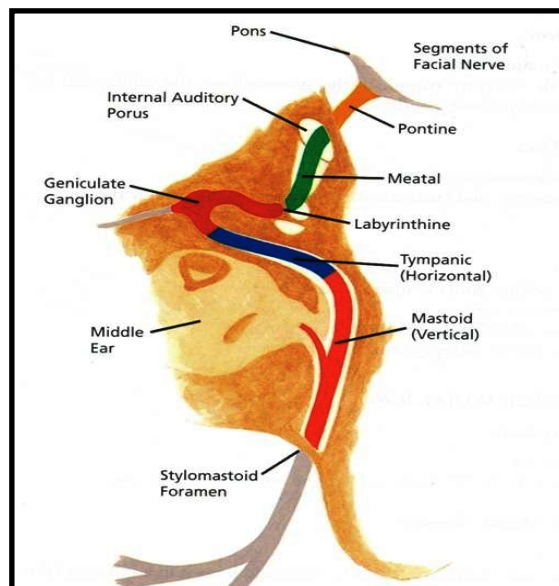


Figure 1.
Facial nerve path

As it courses through the ear (temporal) bone system, the facial nerve sends branches to the tear glands, the tongue and the salivary glands. After leaving the ear's bony structures, it divides again into many branches that serve various facial muscles. The division after it leaves the mastoid is shown in Figures 2 & 3.

Figure 2.
Facial nerve division

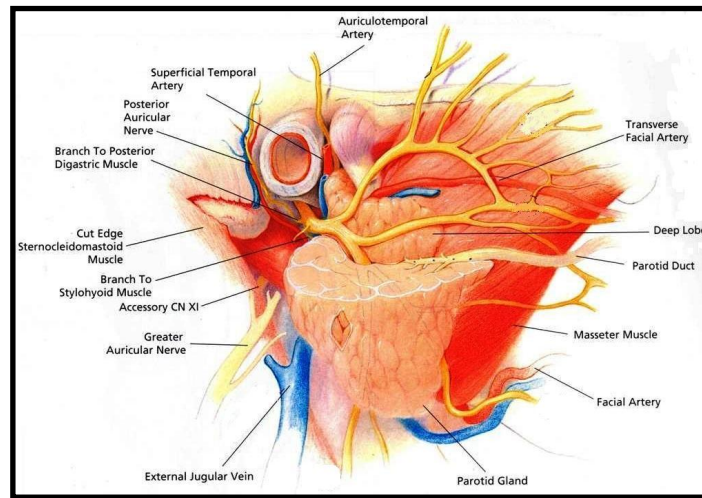
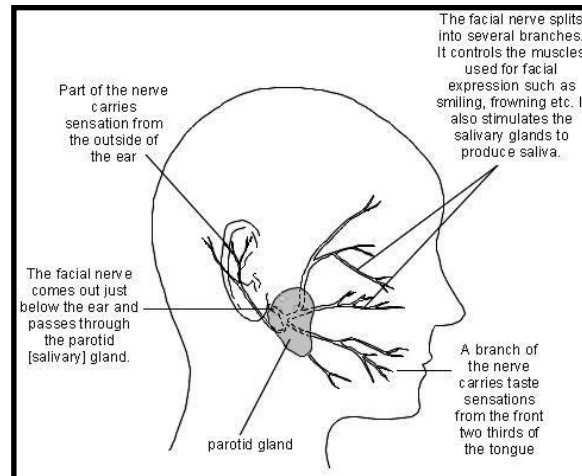


Figure 3.
Facial nerve



Any significant disturbance to the facial nerve may result in temporary facial weakness or paralysis, which in turn causes incomplete eye closure, inappropriate facial movement, dryness or excess fluid in the eye or mouth and/or alteration of taste. Rarely, an acoustic tumor may actually involve the facial nerve. Because of tumor growth, the nerve may be stretched or even engulfed by the tumor. Surgeons mention that a facial nerve, after it has been separated from the tumor is very fragile and easy to tear. The facial nerve is also tiny; as it comes out of the internal auditory canal, it is less than one to two millimeters in diameter.

Fortunately, there are over 8,000 nerve fibers in this tiny structure, like a bundle of wires making up a phone cable.

If the facial nerve is only mildly damaged, the “core” (axon) of the nerve itself will regenerate slowly (approximately one inch per month) all the way back to the muscles in the face. But even with only mild damage, there can be some misdirection of fibers. The regenerating fibers can grow down the wrong nerve channel, leaving a result like crossed wires. This “new connection” can cause inappropriate movement, also called “synkinesis”, such as the eye on the affected side blinking or tearing when one chews. With more severe damage, the insulation (myelin) degenerates and this pathway may be lost. Thus, the gland regulating taste, tearing and muscles controlling eye closure and other facial movement, will not respond to messages sent by the brain.

RANGE OF DAMAGE

Many scales exist for estimating how well the facial nerve is functioning. They provide guidelines for those affected. Though none is perfect, below we provide the most commonly used scale.

HOUSE-BRACKMANN FACIAL NERVE GRADING SCALE

Grade 1. Normal facial function in all areas.

Grade 2. Mild movement weakness, normal symmetry at rest. Slight weakness noticeable on close inspection; may have very slight synkinesis (inappropriate movement with voluntary movement of another muscle), moderate to good forehead motion, complete eye closure with minimum effort, only slight mouth disturbance.

Grade 3. Moderate dysfunction with noticeable asymmetry, good eye closure. Obvious but not disfiguring difference between two sides; noticeable but not severe synkinesis. Normal balance and tone at rest, slight to moderate movement of forehead, complete eye closure with effort, mouth movement slightly weak with maximum effort.

Grade 4. Moderately severe dysfunction with gross asymmetry, incomplete eye closure. Obvious facial weakness and/or disfiguring asymmetry with gross movement. Normal symmetry and tone at rest. No forehead movement on affected side, incomplete eye closure, mouth asymmetric with maximum effort.

Grade 5. Severe dysfunction with minimal facial movement. Only barely perceptible motion with attempted movement. Face unbalanced at rest. No forehead motion, incomplete eye closure. Slight mouth movement possible.

Grade 6. Complete paralysis. No movement.

Facial weakness is usually noted when the patient awakens following surgery. For most people, there will be some improvement within three to six weeks; however, in others there may not be significant recovery for several months after surgery. In a few instances, a part of the facial nerve may have been preserved, but because of severe damage or disruption of necessary blood supply, loss of function may be prolonged or even permanent.

SURGICAL REHABILITATION

The sooner regeneration is noted following surgery, the more likely it is that recovery will be complete. However, it is reasonable to wait up to a year for recovery, before proceeding with facial re-animation, when the surgeon believes that the nerve integrity has been preserved. On the other hand, if the nerve is severed during removal of the tumor, then facial reanimation surgery should be done as soon as the patient's health permits.

It is of utmost importance that facial reanimation is undertaken in a timely fashion to get the best possible outcome. Most importantly if an individual has no movement after one year, they should undergo a thorough evaluation by an experienced facial nerve surgeon.

A. Immediate Repair

1. Direct Nerve Repair

The best time to repair the nerve is at the time of the initial surgery, and at the site of injury. In a few cases, both ends of the severed nerve can be reattached. Better nerve function can be achieved from a direct seventh nerve repair than with any other technique. To perform this, both ends of the delicate nerve must be available, and contain adequate bulk and length to be stitched without tension.

2. Interposition Graft

When the severed facial nerve no longer provides two repairable ends which may be reattached, a grafted section of another nerve may be positioned between the two "connectable" ends. A suitable graft may be obtained from the neck, leg, or arm.

B. Later Repair

Sometimes it is not possible to repair the nerve, even with interposition grafts, because one or both ends may not be suitable for direct attachment. Thus a graft using both ends of the seventh nerve becomes technically impossible.

There are other techniques available that may be performed shortly after tumor removal as the situation and the best alternatives for facial nerve rehabilitation dictate.

1. Hypoglossal – Facial (12/7) Transfer (or Variations like "Jump Grafts")

This technique has been widely used—either immediately to graft the tongue nerve (hypoglossal or 12th facial nerve) on the affected side to the facial nerve on that side, or after a recommended waiting period (usually 12 months) when there has been no return of facial nerve function, even though the nerve was intact at the conclusion of surgery.

To accomplish this "hook-up," the facial nerve is exposed from an incision in front of the ear and the hypoglossal nerve is identified further down in the neck. The 12th nerve is cut (either partly or completely) and the portion coming from the brain is attached to the healthy stump of the facial nerve.

After several months, fibers from the 12th nerve grow within the 7th nerve to the muscles of facial expression. Partial voluntary movement can return; facial motion is initiated by tongue movement. The 12/7 transfer is recommended as soon as there is no possibility of 7th nerve function. If a 12/7 is attempted several years or longer after facial paralysis, it is likely that the facial nerve will be fibrose—filled with scar tissue and unresponsive.

2. Masseteric Facial (5-7) Transfer

Similar to the 12-7 transfer discussed earlier, the masseteric nerve can be used to give input to the paralyzed facial nerve. The masseteric (5th cranial nerve) nerve gets activated when an individual clenches or bites down. It is a natural movement that can be learned to be used by individuals to help them smile after this surgery. The other advantage of 5-7 is that it causes less mass movement than 12-7 and a more natural smile. It can also be used for individuals who have multiple nerve injuries who are not candidates for 12-7.

3. Regional Muscle Transfer

Regional muscle transfers are surgical options for individuals with long-standing facial paralysis who are not great candidates for 12-7, 5-7, or free muscle transfers such as gracilis flap. The most common regional muscle used in facial reanimation is the temporalis. In this procedure the end of the muscle or its tendon (orthodromic temporalis tendon transfer) is attached to the corner of the mouth. When the individual bites down or clenches, the patient's face recreates a smile. This operation also improves the tone and the static position of the face.

4. Free Muscle Transfer

In some cases, it is possible to transplant a muscle from the inner thigh or back to restore the smile. This can be done as a one-stage or a two-stage procedure and can sometimes result in a completely natural, spontaneous smile when successful (Figure 4).

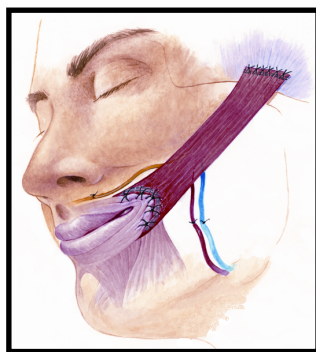


Figure 4.
Free muscle transfer

5. Static Procedures

There are “static” (providing tone rather than movement) procedures that can improve facial sagging and supplement the above techniques. They include a browlift, facelift and other tendon or fascial (connective tissue) slings.

C. Eye Reanimation Techniques

Surgical procedures to improve lid position and preserve a diminished tear supply are discussed at length in the ANA booklet, *Eye Care after Acoustic Neuroma Surgery*.

With facial paralysis, protection of the cornea is most imperative. A patient with facial paralysis who has lost tearing and eye sensation, or who has poor coverage of the cornea when eye closure is attempted, should be considered for eyelid reanimation without delay. Cornea protection and eye lubrication are necessary for the health of the eye. Both should be attainable without having to sew the eyelids together (tarsorrhaphy).

Canthoplasty (tightening of the tendons of the corner of the eye), implantation of a gold or platinum weight or wire spring, and blocking the tear drainage system are some of the surgical possibilities for eyelid reanimation and tear preservation.

For more information, see the booklet mentioned above, your ophthalmologist or facial nerve specialist.

D. Surgical Interventions for Synkinesis

When patients have a beneficial response to Botox injections, there are several interventions, either office-based or in the operating room, that can create a more long lasting or permanent effect. Amongst these procedures we include platysmectomy (removal of a strip of platysma to stop excessive neck pulling), and highly selective neurolysis of the grimacing or frowning muscles to improve upward smile movement and reduce tension in the neck.

NON-SURGICAL THERAPIES FOR FACIAL MUSCLE

MAINTENANCE AND REHABILITATION

When the facial nerve has been damaged or stretched by tumor growth or removal, a temporary weakness usually results while the nerve regenerates. The facial nerve must heal before an exercise program can be effective, so intensive therapy is not recommended during this time (much like a broken bone in a cast has to heal before beginning an exercise program). Avoid exercising the face too early to reduce the tendency for the unaffected side to take over and create even more asymmetry. New research suggests that gently stroking your fingers over the affected side from the eye toward the mouth, from the ear toward the corner of the mouth and from the back of the jaw under the earlobe toward the lower lip, may result in more accurate nerve healing. Pay attention to the sensation as the fingers slide over the facial skin. Doing so may help the brain “maintain connection” to the affected side while the movement sensation signals are absent.

Give yourself permission to rest and let the nerve heal. Watch for small facial movements to become visible as nerve recovery progresses. Several self-administered therapies could help promote normalized facial movements after recovery begins. Beware of electrical stimulation therapy which is often recommended. These stimulations may increase the chance of synkinesis or aberrant nerve regeneration.

A. Exercises

Patients with facial weakness should be aware of facial “posture.” Therapists suggest keeping the muscles on the unaffected side relaxed. Doing so will prevent the unaffected side from “pulling over” the affected side and help maintain facial symmetry.

Among other things, the facial muscles are designed to create facial expressions. These expressions convey emotional signals that are crucial for non-verbal communication between human beings. Facial expression is almost always subconscious and automatic. We rarely think of how we move our face during spontaneous situations or how many different expressions we use. Typical, functional, facial expressions are small and subtle, never forced with great effort. For optimal results, facial “exercises” should mimic the normal functional usage of the muscles, so they should be soft and gentle. Keeping this concept in mind, the following movement patterns performed softly and easily (never forced) may be helpful as facial function returns. Do not let the unaffected side work harder or go further than the affected side. Exercising in this manner will create tiny movements at first, but in the long run it will reinforce good facial symmetry and balance and more accurately mimic the normal, unconscious, facial movements we use everyday.

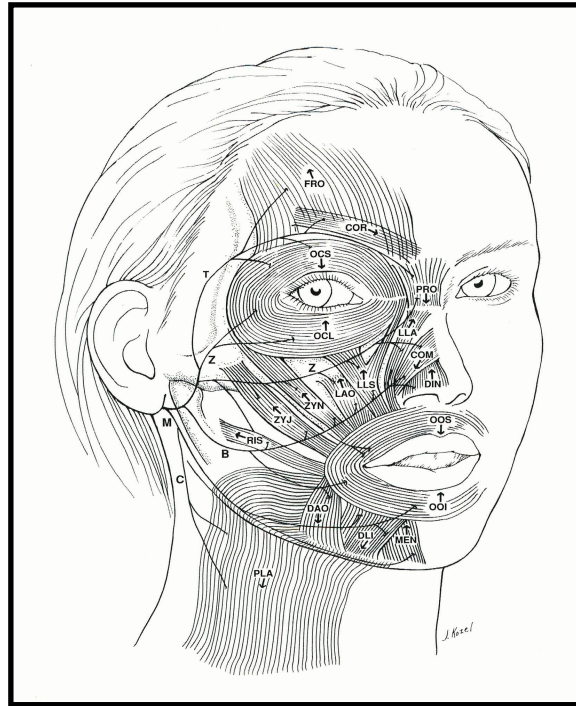
- Softly raise eyebrows
- Draw eyebrows down and together
- Raise upper lip while wrinkling nose, as though something smells bad. Watch for development of the crease between the side of the nose and the corner of the mouth. This is called the nasolabial fold.
- Focus eyeballs in downward direction - softly close both eyes
- Softly pucker lips – as though blowing a light feather
- Softly smile - think of smiling from the upper cheek rather than with the lips – don’t let the unaffected side smile larger than the operated side
- Watch in a mirror while speaking on the telephone to maintain symmetry
- DO NOT chew gum as this promotes asymmetry

Neuromuscular Re-Education Techniques

A number of therapists in the United States specialize in neuromuscular re-education techniques which can help improve facial expression and symmetry once movement begins to return.

The principle underlying this therapy is that the plasticity of the brain (i.e., ability to learn new movements) allows for retraining abnormalities that result from a damaged facial nerve. This is especially helpful in cases where incomplete recovery has resulted in abnormal facial movements known as synkinesis. Specially trained therapists combine individual evaluation, specific movement patterns, massage and biofeedback to normalize the abnormal movements that can occur with faulty nerve regeneration. In many cases of synkinesis, the lack of function can be attributed to improper coordination as opposed to (or in combination with) muscle weakness. The main focus when retraining synkinesis is on reducing the inappropriate, uncoordinated muscle movements that distort expression, while improving muscle coordination to enhance expression.

Figure 5.
The arrow on each muscle indicates the direction that muscle moves when it contracts.



With good training and practice, many acoustic neuroma “alumni” with weak or uncoordinated facial movement have retrained existing nerve pathways, resulting in additional or improved function.

Success depends on patient motivation and willingness to follow a detailed program in the clinic followed by daily practice of a home program. Consistent practice is necessary to learn the new, more functional, movement patterns.

B. Massage

Massage can be helpful in all phases of recovery. Initially, *very gentle*, massage feels good and promotes blood flow and brain connection to the affected side. As the nerve regenerates, facial tightness, stiffness or spasm may occur. In these cases massage can help relax the overly tight muscles.

C. Heat

Some therapists mention the application of mild heat (microwaveable heat pack, warm towels, a heating pad, or hot water bottle) to stimulate blood supply to the facial muscles or to relax tight overactive muscles. This technique is especially helpful for reducing facial spasms that can be associated with synkinesis. A microwaveable heating pack is a convenient way to apply heat to the affected face and neck. Be certain that the heat pack is not too hot. If there is loss of sensation on the affected side, test the heat on the unaffected side first to avoid burns.

D. Vibration and Electrical Stimulation

Some therapists recommend limited use of a small, flat vibrator for short periods to accompany facial muscle exercises. There is little evidence that vibration is beneficial. Electrical stimulation should not be used at any time during the healing phase as it may interfere with normal nerve regeneration and/or reinforce abnormal movement patterns. It also may increase synkinesis.

E. Acupuncture

The effect of acupuncture on facial recovery is unknown. There is little evidence that it either assists in or interferes with facial nerve recovery. Many patients have reported improvements in headaches or a greater sense of well being and relaxation after undergoing acupuncture. Be aware of electrical stimulation as it may increase the chance of synkinesis.

F. Other techniques

In recent years, several facial exercise programs have been advertised in TV infomercials. Regardless of the fact that scientific research is lacking, these techniques were marketed to reduce the signs of aging in normal faces, not to rehabilitate facial paralysis. Their use could promote asymmetry, synkinesis or facial spasm.

G. Botox® (Botulinum toxin)

Botox has received a great deal of media attention as a cosmetic procedure for reducing wrinkles. It is also being used increasingly in cases of facial paralysis with synkinesis, to improve facial coordination. Botox blocks the electrical signal generated by the facial nerve

from entering the muscle. The portion of the muscle injected becomes paralyzed and cannot move. The effect is temporary, lasting 3 to 6 months. When injected selectively into improperly contracting muscles, Botox can effectively reduce some of the abnormal contractions and improve coordination; however, it can cause severe paralysis if injected in the wrong place. Botox must be administered by a qualified physician who has experience with facial paralysis and synkinesis.

H. Cosmetic Considerations

Facial appearance and symmetry can be enhanced by hairstyle, cosmetic application or tinted eyeglasses. A cosmetologist can help in designing individualized techniques to improve appearance as the facial nerve recovers.